



## Chondroblastoma of the femoral head disrupting the articular cartilage *Description of a novel surgical technique*

Panagiotis GIVISSIS, Filon AGATHANGELIDIS, Evangelos CHRISTODOULOU, Anastasios CHRISTODOULOU

*From Aristotle University of Thessaloniki, Greece*

**Chondroblastoma is a rare benign tumour. Involvement of the femoral head may often lead to a delayed diagnosis.**

**We present the case of a 15-year-old patient with right hip pain which was first attributed to adductor tendinitis. Following aggravation of the symptoms, thorough investigation including a CT-guided biopsy, revealed the diagnosis of chondroblastoma of the femoral head. Removal of the lesion based on the techniques described in literature was not possible, mainly because the articular cartilage was breached. A novel surgical technique was used in order to address the rare location and behaviour of the tumour. This technique offered the patient pain relief and return to his previous every day and sports activities. No recurrence was seen at two years follow-up.**

**Keywords :** chondroblastoma ; femoral head ; bone allograft.

---

### INTRODUCTION

Chondroblastoma of bone is a rare benign primary tumour ; it accounts for one to two percent of primary bone tumours. Two thirds of the patients are male in their second decade of life (8,9,11). It arises from the cartilaginous growth plate and common sites are the proximal humerus, proximal tibia, proximal and distal femur. It is also rare for the tumour to violate the articular cartilage (8).

The femoral head is the third most common site. Curetage and bone grafting is the usual treatment

but there is no gold standard especially with femoral head lesions because of the difficult approach. In the skeletally immature patient, chondroblastoma is surrounded on one side by articular cartilage and on the other by epiphyseal cartilage. One must decide which side will be violated in order to remove the tumour (11).

We report on a patient with a chondroblastoma of the femoral head which had breached the articular cartilage. Review of the literature showed that lesions which involved the joint at the time of presentation were not common. As a result we performed an innovative surgical technique which to the best of our knowledge has not been described before.

---

■ Panagiotis Givissis, MD, PhD, Assistant Professor.

■ Filon Agathangelidis, MD, Consultant.

■ Evangelos Christodoulou, MD, Resident.

■ Anastasios Christodoulou, MD, PhD, Professor.

*1st Department of Orthopaedics, Aristotle University of Thessaloniki, G. Papanikolaou General Hospital, Thessaloniki, Greece.*

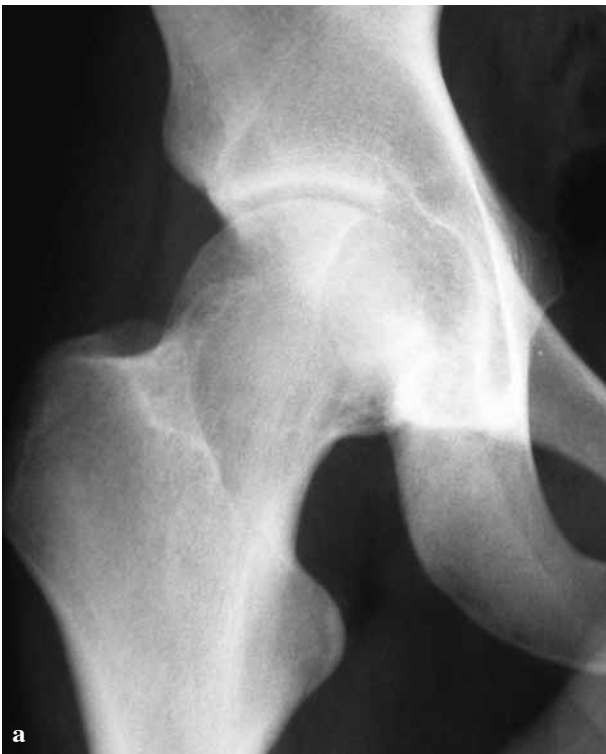Correspondence : Filon Agathangelidis, Str. Sarafi 39A, Kalamaria, 55132 Greece. E-mail : fagath@gmail.com

© 2012, Acta Orthopædica Belgica.

---

*Conflict of interest statement : Each author certifies that he or she has no commercial associations (eg, consultancies, stock ownership, equity interest, patent/licensing arrangements, etc) that might pose a conflict of interest in connection with the submitted article.*

*Full informed consent has been taken from patient and his parents that data from his health file will be used for scientific reasons.*



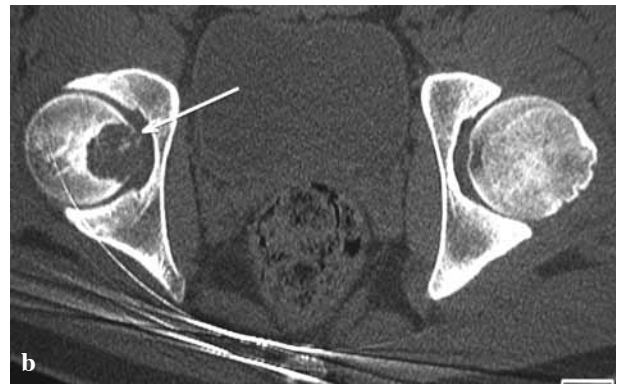
*Fig. 1a.* — AP radiograph of the pelvis showing a lytic lesion of the right femoral head.

### SURGICAL TECHNIQUE – CASE REPORT

A 15-year-old male presented with a 16-month history of right hip pain. He was an active young man involved in soccer and reported two incidents of minor trauma which aggravated pain and caused him to avoid sports activities for almost a year. He was treated elsewhere for adductor tendinitis but in the meantime started suffering from night pain and a limp.

On physical examination the patient appeared healthy and stable. On palpation there was some tenderness over Scarpa's triangle but no palpable tumour or lymph nodes. There were also no signs of infection around the hip. Range of motion was full but painful on internal rotation more than 10 degrees. There was no leg length discrepancy and neurovascular examination of the lower limbs was normal.

Plain radiographs of the affected hip revealed a lytic lesion of the femoral head with no periosteal

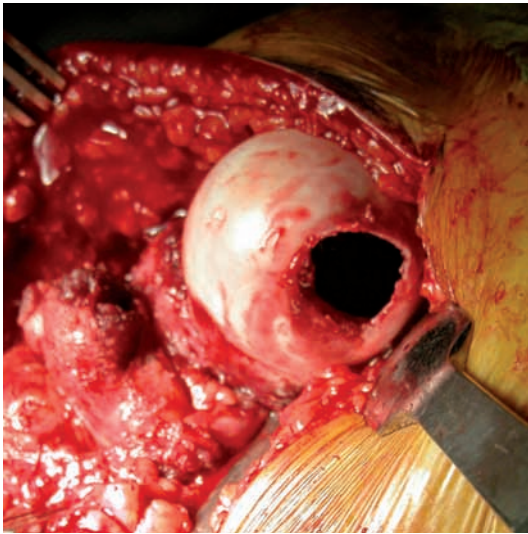


*Fig. 1b.* — CT scan of the hip showing penetration of the hip joint by the lesion.

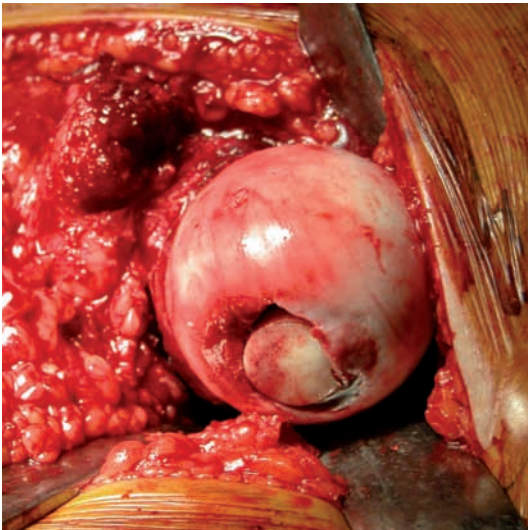
reaction (Fig. 1a). A CT scan showed a lytic lesion two centimeters in diameter which penetrated the hip joint (Fig. 1b). The MRI scan showed a cystic lesion with sclerotic margins and internal septa. The cortex was breached and there was synovitis of the right hip. Finally bone scintigraphy with Tc99 and Tc99m Sestamibi clarified that there was increased osteoblastic activity with benign characteristics. The patient underwent a CT guided needle biopsy, the specimens were examined histologically and a diagnosis of benign chondroblastoma was made.

In surgery the patient was placed in the lateral decubitus position and a Hardinge approach was used. A T-shaped capsulotomy was performed and the hip was anteriorly dislocated and externally rotated in order to bring the lesion under direct vision. The lesion was thoroughly excised and this left a conical defect (Fig. 2). Appropriately sized round trephines with cutting edges were used to procure a bone graft of suitable size and shape from a freeze dried femoral head ; the graft was used to fill the gap. The graft was press fitted in place in such a manner that the femoral head's shape and congruity was restored as much as possible. The graft was tested for stability and no other technique of stabilization was deemed necessary (Fig. 3). Histological examination of specimens taken intra-operatively confirmed the initial diagnosis of chondroblastoma.

The patient was mobilized with partial weight bearing for eight weeks. He was immediately relieved from pain and two years post-op imaging

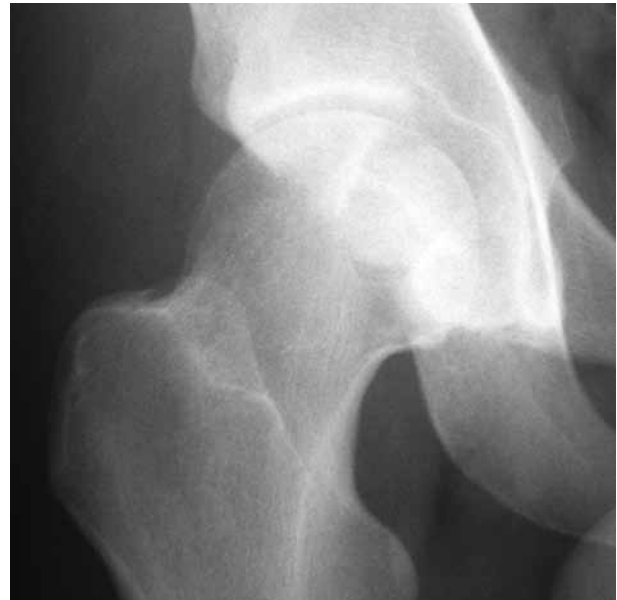

**Fig. 2.** — Conical defect of the femoral head after excision of the chondroblastoma.



**Fig. 3.** — The femoral head with the bone allograft impacted into place.

with radiographs and CT scan shows good bone graft integration with no collapse and no arthritic changes of the hip joint (Fig. 4). MRI at 12 and 24 months post-op showed progressive integration at the host to graft junction and no signs of local recurrence. The patient has returned to his normal everyday and sports activity free of pain.



**Fig. 4.** — Two-year follow-up AP radiograph of the right hip. The femoral head congruity is restored. There is a small gap between the graft and the head but there is no collapse of the graft and no arthritic change in the hip joint.

## DISCUSSION

Various techniques have been described for the removal of chondroblastomas of the femoral head. What makes this case unique is that none of the techniques described was appropriate for our patient. We had a lesion 2 cm in diameter which had destroyed the articular margin and entered the hip joint. This is a very rare characteristic to chondroblastomas (1). Therefore the patient needed a surgical technique which would help to adequately remove the lesion in order to avoid the common complication of local recurrence but also that would preserve the hip joint and prevent the development of osteoarthritis.

The technique mostly resembling to ours is the one published by Stilli *et al* (10) where a large part of the femoral head – approximately one third as seen on the radiographs – was resected and replaced with properly contoured femoral head graft. Because of the size and shape of the graft additional fixation with a Herbert screw was necessary. The difference with our patient is the size of the lesion.

We did not have to sacrifice that much of the femoral head in order to excise the tumour. Furthermore in our case the graft was simply impacted with no need for further fixation.

Strong *et al* (11) reported on ten patients half of which underwent curettage via the femoral head and the other half curettage via direct approach. It was not specified whether there was penetration of the hip joint by the tumour in any of the cases.

Three patients reported by Erickson *et al* (2) and Petsas *et al* (6) underwent radiofrequency ablation. In one of the patients (6) the cortex anteriorly was disrupted. Although the lesion reduced in size one year after the intervention the patient was advised to protect his hip from extreme activities and a yearly follow-up was suggested.

There are four more cases (1,3,4,7) where various techniques are used. There is no report in any of the above that the hip joint was involved, and various techniques were used: muscle pedicle bone grafting (1), a trapdoor procedure (3), a rotational acetabular osteotomy (4) and bone grafting along with prophylactic internal fixation (7). None of the above techniques were suitable for our patient as they were not addressing the main problem which was hip joint penetration.

One may raise the issue of the graft not being completely vascularised in such cases. Parks (5) has studied cross section radiographs and histology of allografts used in cemented total knee replacements. The authors concluded that the allografts consisted of acellular bone that had not been revascularized and that new bone has been laid down only at the host to graft junction. However all grafts were dense and intact and the trabeculae showed no signs of collapse or resorption. This conclusion supported our decision to use this grafting technique. We also had the advantage that the area reconstructed is a non weight-bearing area of the femoral head and that minimal discrepancies between the diameter of the graft and the defect would be tolerated.

Chondroblastomas of the femoral head still remain a challenge. They are benign but painful

tumours which need thorough excision in order to avoid local recurrence. Because of the position of the tumour, adequate exposure without unnecessary damage to the articular or epiphysial cartilage requires careful planning. Fortunately penetration of the cortex by the tumour is rare. In this unfortunate event our technique is able to preserve the hip joint and restore congruity. The two-year follow-up of our patient suggests the successful midterm treatment of a difficult problem but still the late occurrence of osteoarthritis is a major concern.

## REFERENCES

1. Diwanji SR, Cho SG, Kong IK, Yoon TR. Hip pain in a 24-year-old woman. *Clin Orthop Relat Res* 2007 ; 461 : 262-268.
2. Erickson JK, Rosenthal DI, Zaleske DJ, Gebhardt MC, Cates JM. Primary treatment of chondroblastoma with percutaneous radio-frequency heat ablation : report of three cases. *Radiology* 2001 ; 221 : 463-468.
3. Iwai T, Abe S, Miki Y, Tokizaki T *et al*. A trapdoor procedure for chondroblastoma of the femoral head : a case report. *Arch Orthop Trauma Surg* 2008 ; 128 : 763-767.
4. Maezawa K, Nozawa M, Takagi T *et al*. Rotational acetabular osteotomy for benign chondroblastoma of the femoral head. A case report. *J Bone Joint Surg* 2005 ; 87-A : 1358-1362.
5. Parks NL, Engh GA. Histology of nine structural bone grafts used in total knee arthroplasty. *Clin Orthop Relat Res* 1997 ; 345 : 17-23.
6. Petsas T, Megas P, Papathanassiou Z. Radiofrequency ablation of two femoral head chondroblastomas. *Eur J Radiol* 2007 ; 63 : 63-67.
7. Rajaram A, Tamurian RM, Reith JD, Bush CH. Hip pain in an 18-year-old man. *Clin Orthop Relat Res* 2008 ; 466 : 248-254.
8. Ramappa AJ, Lee FY, Tang P *et al*. Chondroblastoma of bone. *J Bone Joint Surg* 2000 ; 82-A : 1140-1145.
9. Springfield DS, Capanna R, Gherlinzoni F, Picci P, Campanacci M. Chondroblastoma. A review of seventy cases. *J Bone Joint Surg* 1985 ; 67-A : 748-755.
10. Stilli S, Marchesini Reggiani L, Boriani L, Donzelli O. Osteochondral allograft in a femoral head chondroblastoma : a case report. *Hip Int* 2010 ; 20 : 280-283.
11. Strong DP, Grimer RJ, Carter SR, Tillman RM, Abudu A. Chondroblastoma of the femoral head : management and outcome. *Int Orthop* 2010 ; 34 : 413-417.